

# Innovating imaging techniques to understand

## Atopic Dermatitis skin

Raman Maiti<sup>\*a</sup>, Robert Byers<sup>b</sup>, Simon G Danby<sup>c</sup>, Meng Q Duan<sup>b</sup>, Elaine J Pang<sup>d</sup>, Matthew J Carré<sup>a</sup>, Roger Lewis<sup>a</sup>, Michael J Cork<sup>c</sup>, Stephen J Matcher<sup>e</sup>

<sup>a</sup>Department of Mechanical Engineering, University of Sheffield (UoS), Sheffield, UK

<sup>b</sup>Department of Materials Science and Engineering, UoS, Sheffield, UK

<sup>c</sup>Infection, Immunity and Cardiovascular Disease, UoS, Sheffield, UK

<sup>d</sup>Medical School, UoS, Sheffield, UK

<sup>e</sup>Department of Electronic and Electrical Engineering, UoS, Sheffield, UK

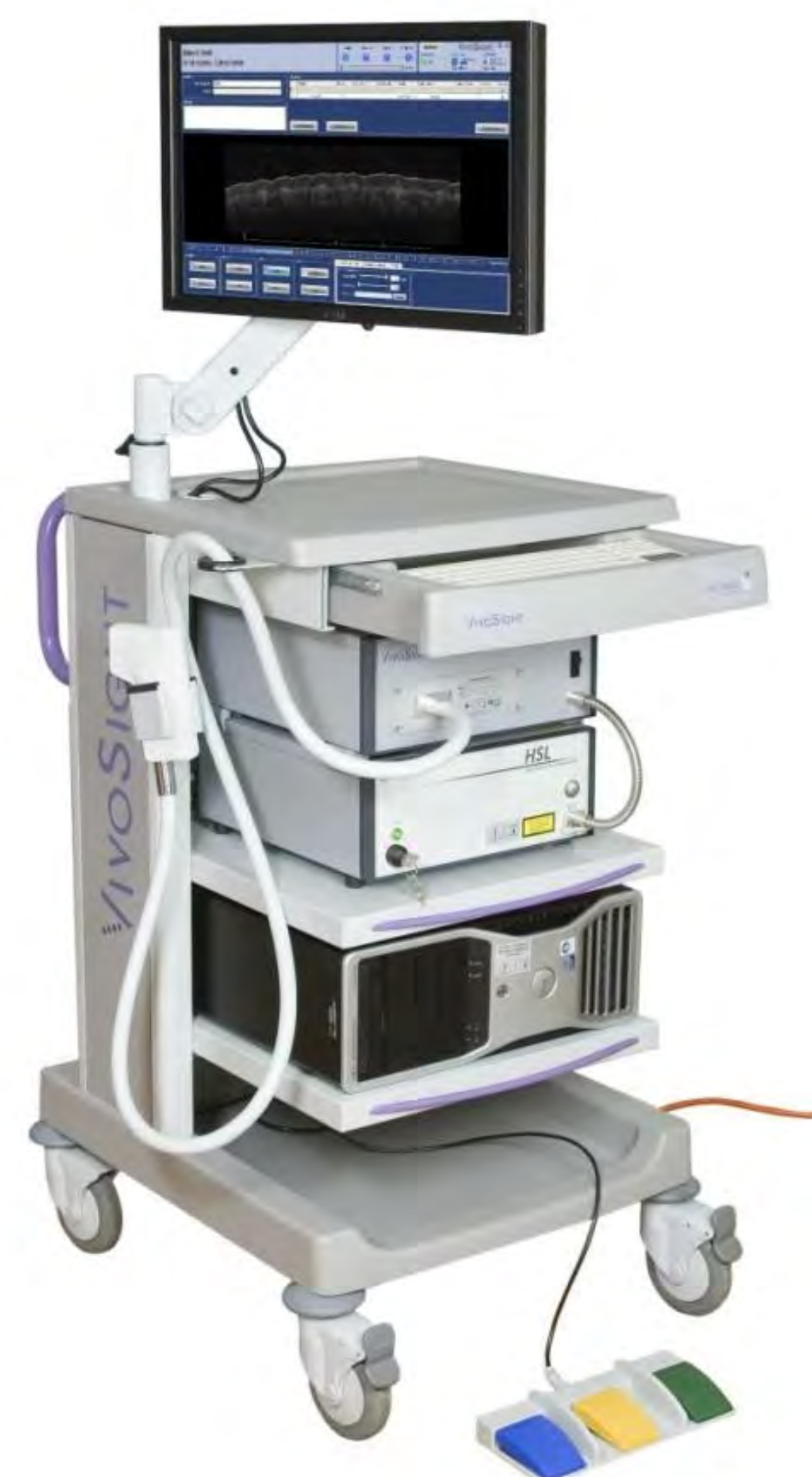

Human Interaction Group

### 1. Why?

- Quantification of skin changes is required to understand skin ailments and monitor the treatment effects [1].
- **Aim: Quantify the morphological (thickness, roughness/irregularity of top surface & junction) and functional (vascular density & architecture) characteristics of atopic dermatitis skin and compare them with unaffected volunteers using non-invasive imaging.**
- Application includes stratification in patient skin and assessment of treatments on skin.

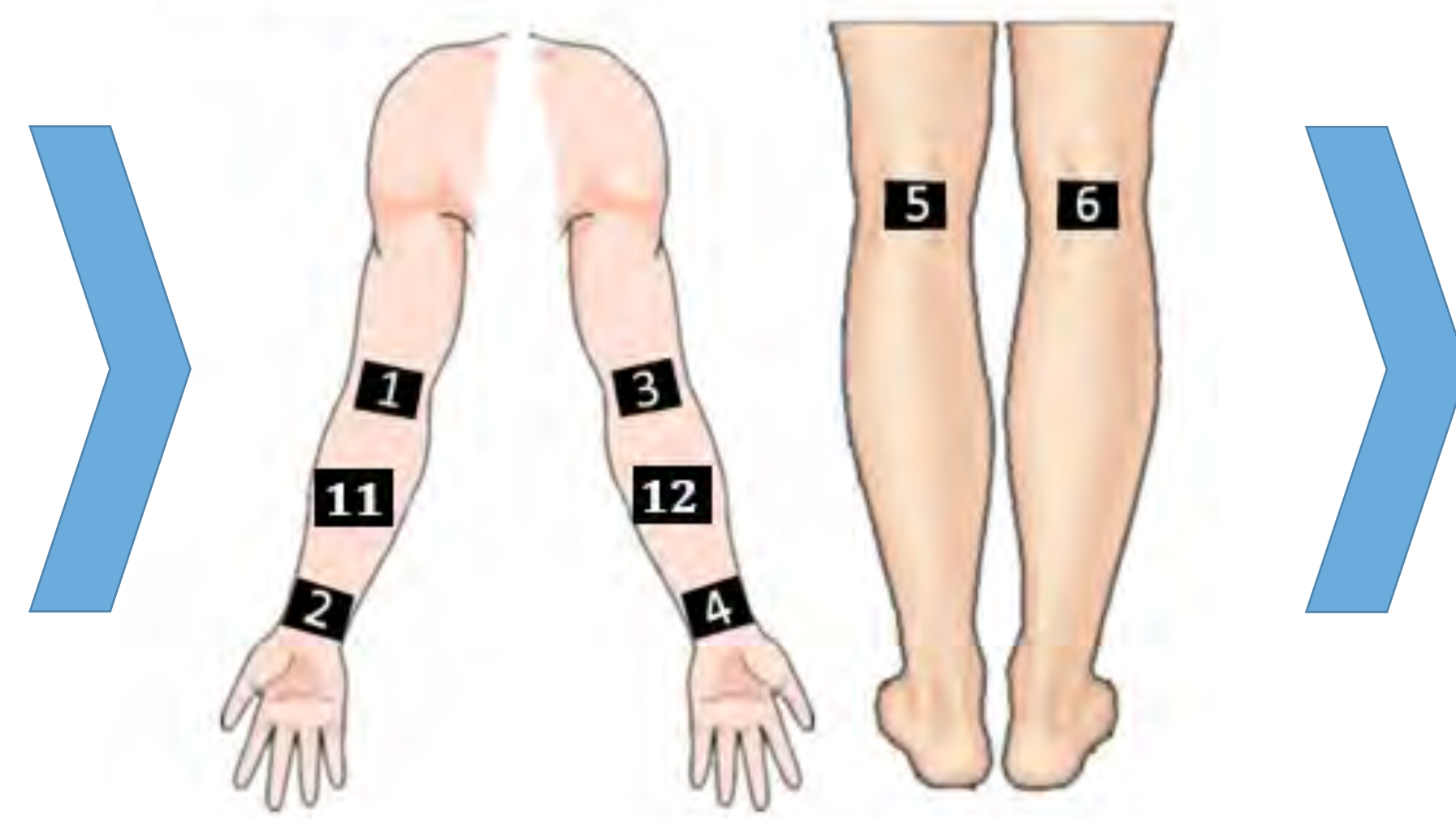
### 2. How?



Optical Coherence Tomography system (VivoSight<sup>®</sup>) with 20kHz A-scan rate and 1300nm centre wavelength.

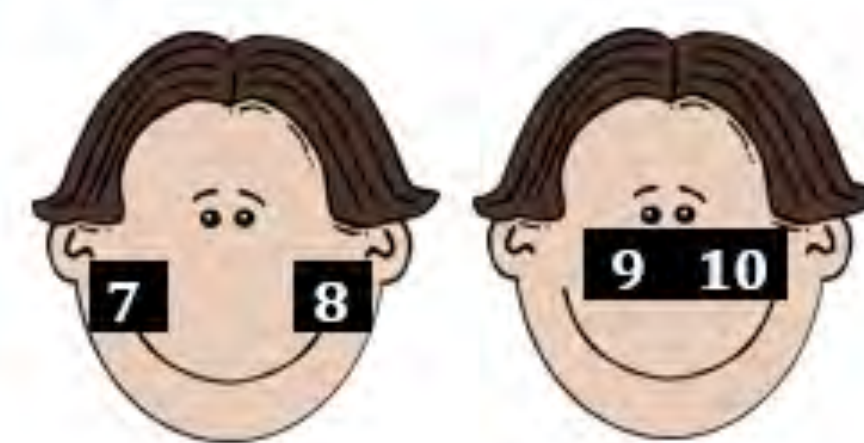
#### Participants:

- 12 healthy volunteers with no history of chronic skin disease.
- 12 Atopic Dermatitis (AD) patients with mean severity (SCORAD) of 20±9.



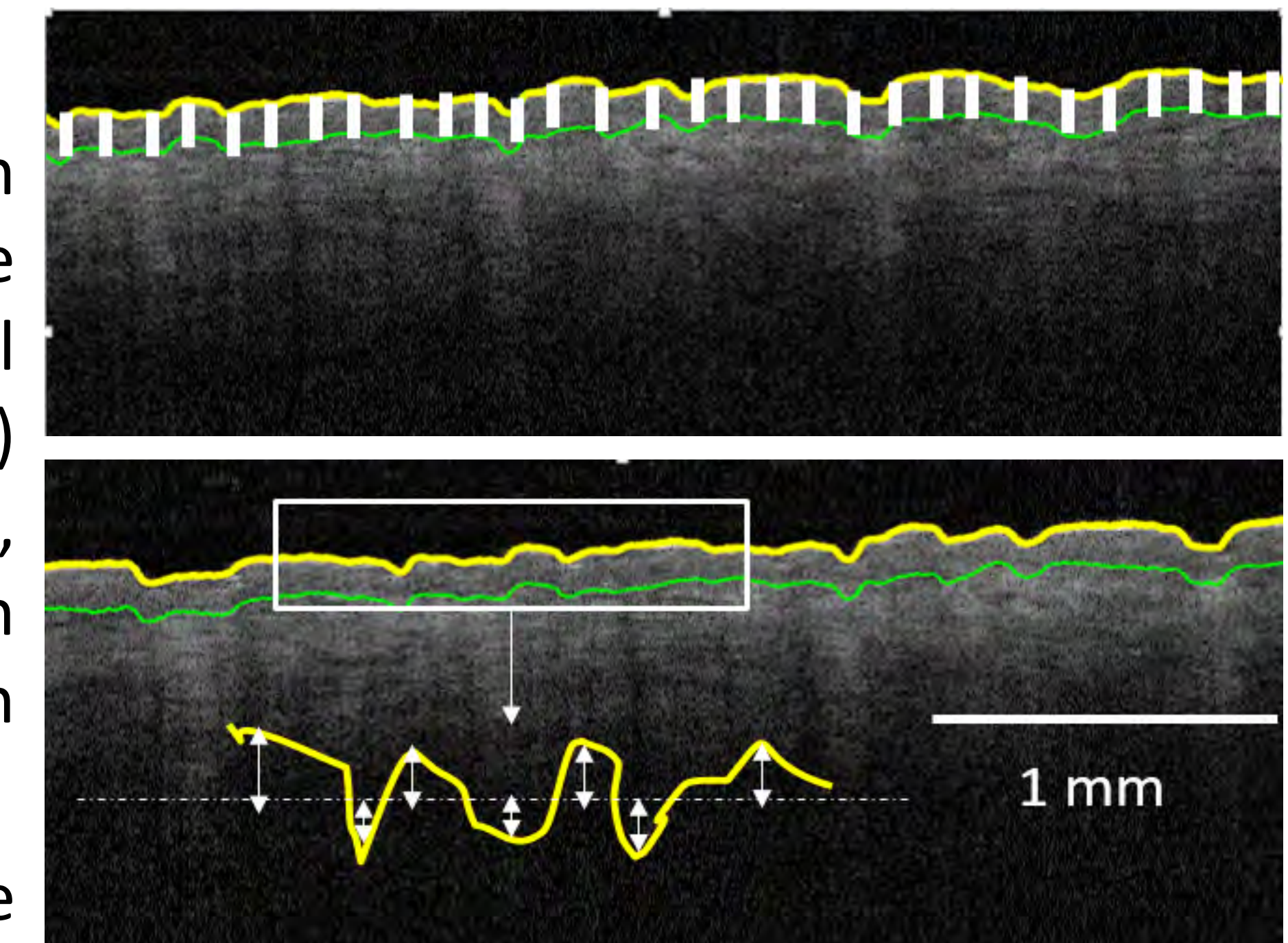
#### Test sites:

Cheeks, eyes, cubital fossa, volar forearm, wrist, popliteal fossa

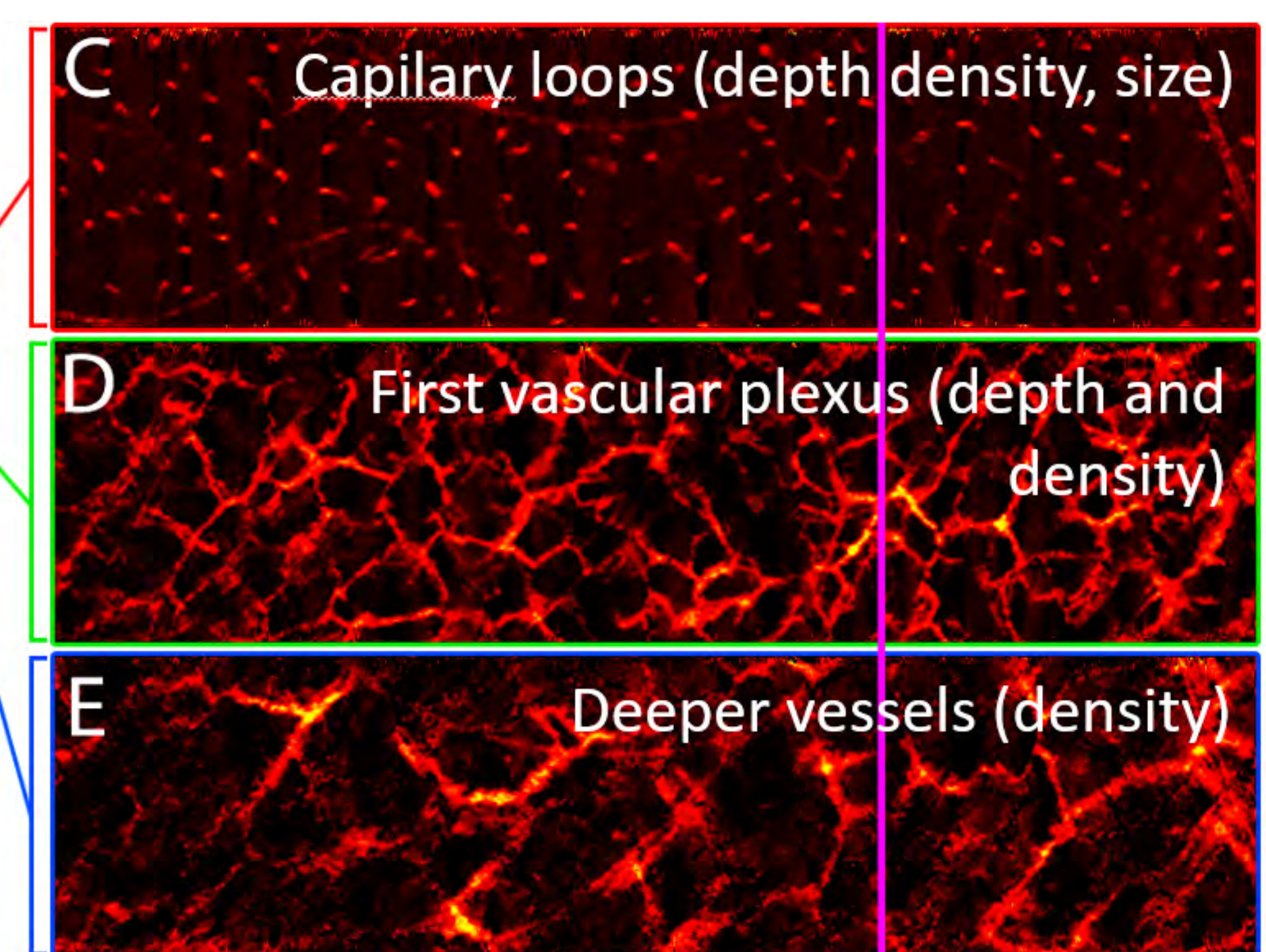



#### Analysis + Statistics:

- Data represented in mean ± SD with one way ANOVA statistical significance (\*p<0.05) between healthy skin, AD skin with no lesion (AD-NL) and AD skin with lesion sites (AD-L).
- Relative percentage thickness (in %) plotted against SCORAD score.



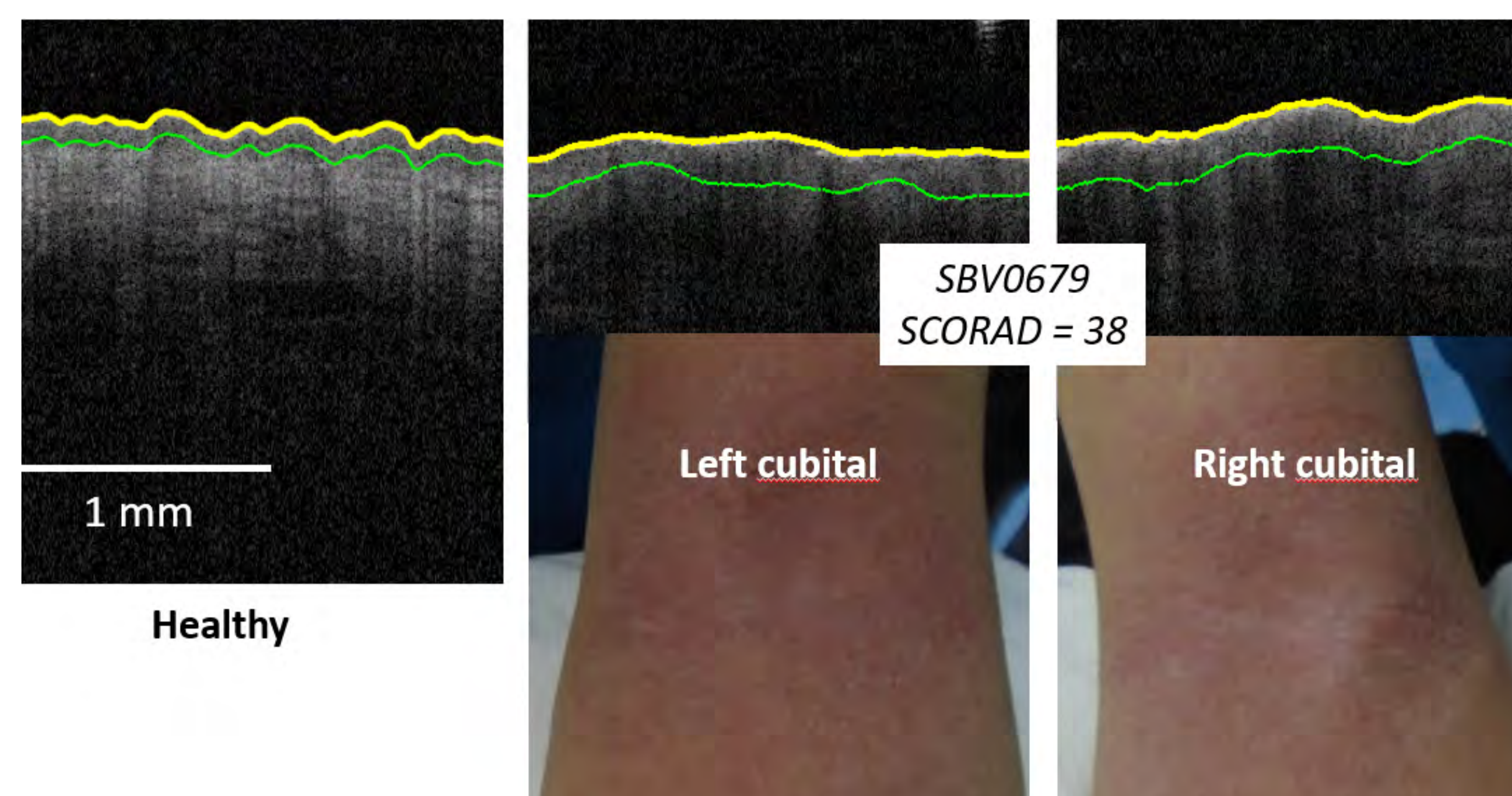
Morphological Parameters [2]



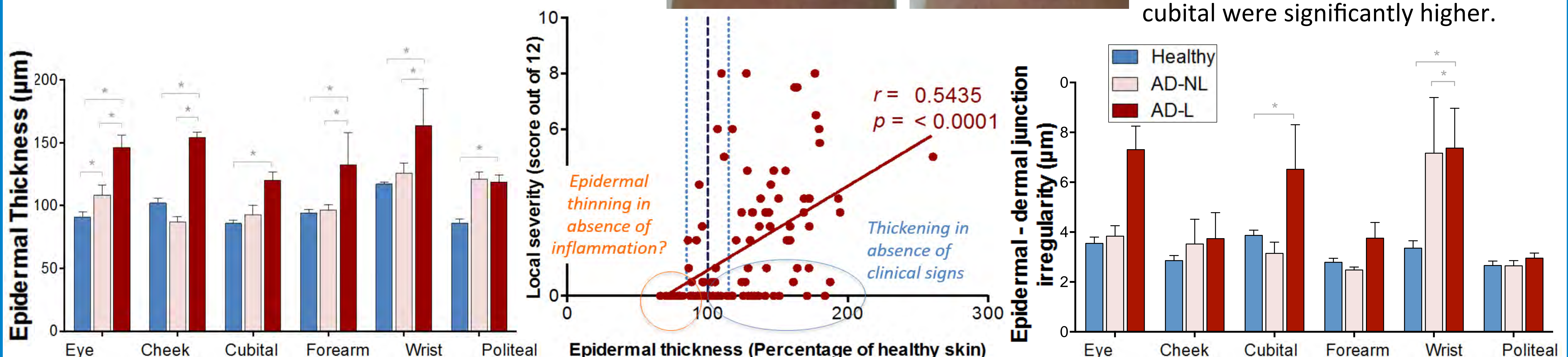
Angiographic Parameters

### 3. What?

- Figures show up to 200% increase in epidermal thickness of an AD volunteer skin sites against healthy skin.
- Good correlation between local severity and relative epidermal thickness was observed. The higher the severity score, the higher the thickness.



- Few sites show thinning and thickening in absence of clinical signs or inflammation as shown in circles.
- Capillary loops become elongated when excessive epidermal thickening has occurred.
- Top surface roughness did not change significantly (\*p>0.09). However, Epidermal-dermal junction irregularities at eye-bag, wrist and cubital were significantly higher.



### 4. Conclusions - Morphological and Angiographic OCT techniques are very promising for quantifying skin inflammation and assessing treatment effects. Similar method has been applied to study other skin ailments such as foot blisters and pressure ulcers.